

3. A 36-year-old woman is admitted to the ICU after an episode of witnessed, out-of-hospital, sudden cardiac arrest for which she received bystander CPR. By the time paramedics arrived, she was awake and neurologically intact. She again lost consciousness during transport and the rhythm seen in Figure 3-B was recorded. She spontaneously converted back to sinus rhythm after 30 s.

In the ED, she reported no prodrome of chest pain or shortness of breath. A 12-lead ECG was obtained (Figure 3-A). Her serum troponin level is normal. Review of her old records revealed an ECG that had been obtained 3 months ago (Figure 3-C). Her past medical history is significant for idiopathic pulmonary arterial hypertension for which she takes bosentan, tadalafil, treprostenil, bumetanide, and warfarin. She recently was diagnosed also with asthma, allergic rhinitis, and depression, and was prescribed fluticasone-salmeterol, escitalopram, and promethazine. Her serum potassium level is 3.8 mEq/L (3.8 mmol/L), serum magnesium level is 2.2 mEq/L (2.2 mmol/L), and international normalized ratio is 2.9. Which of the following is the most appropriate intervention to reduce her future risk of sudden cardiac death?

- A. Start procainamide.
- B. Have her take daily magnesium supplements.
- C. Insert an automatic implantable defibrillator.
- D. Stop promethazine and escitalopram.

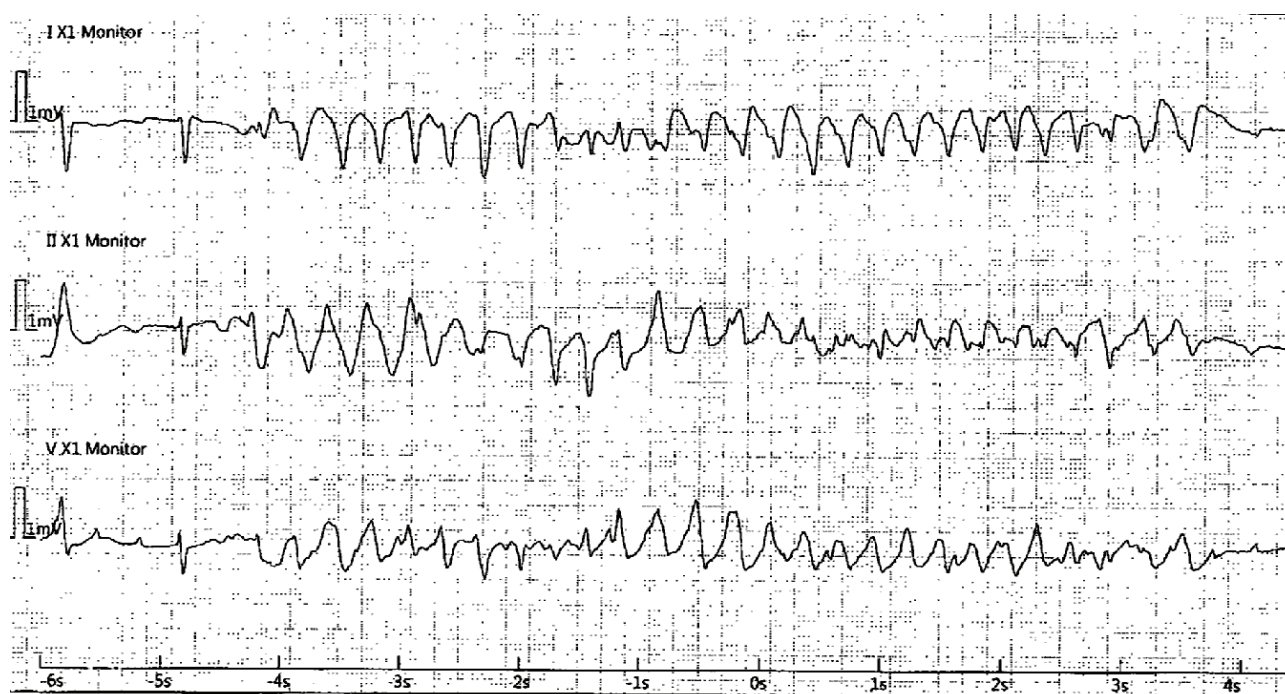


Figure 3-A The patient's 12-lead ECG tracing.

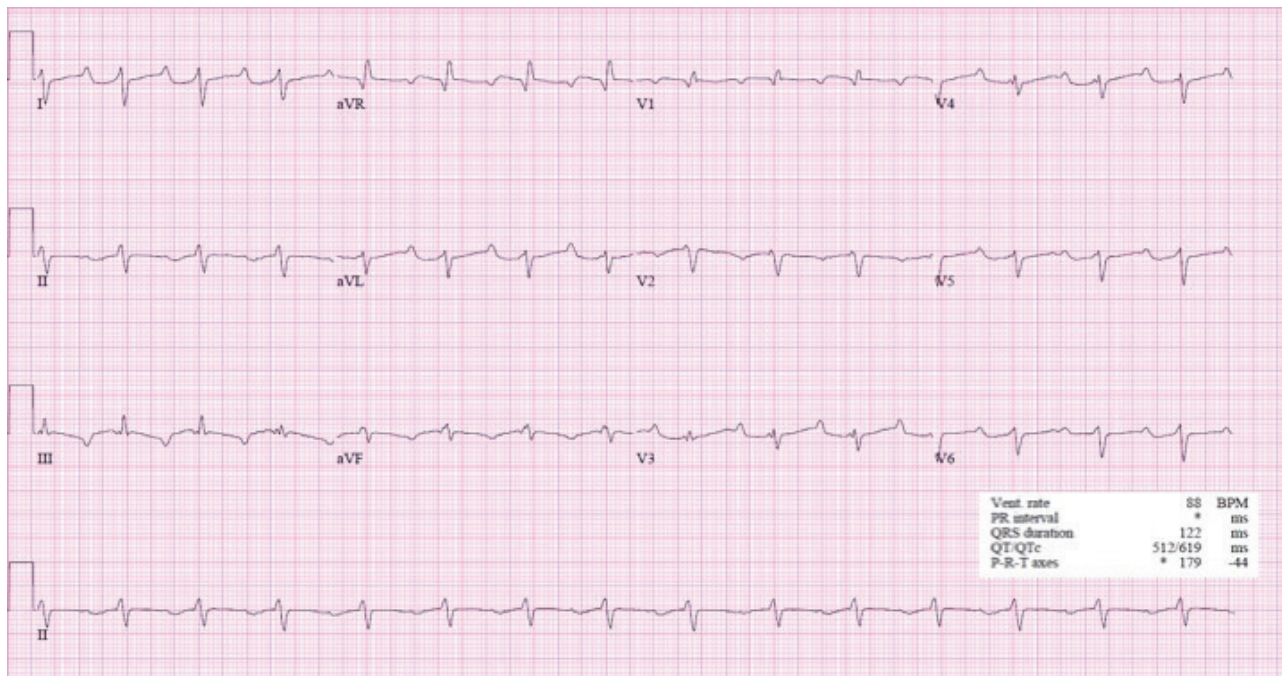


Figure 3-B The patient's ECG tracing during transport.

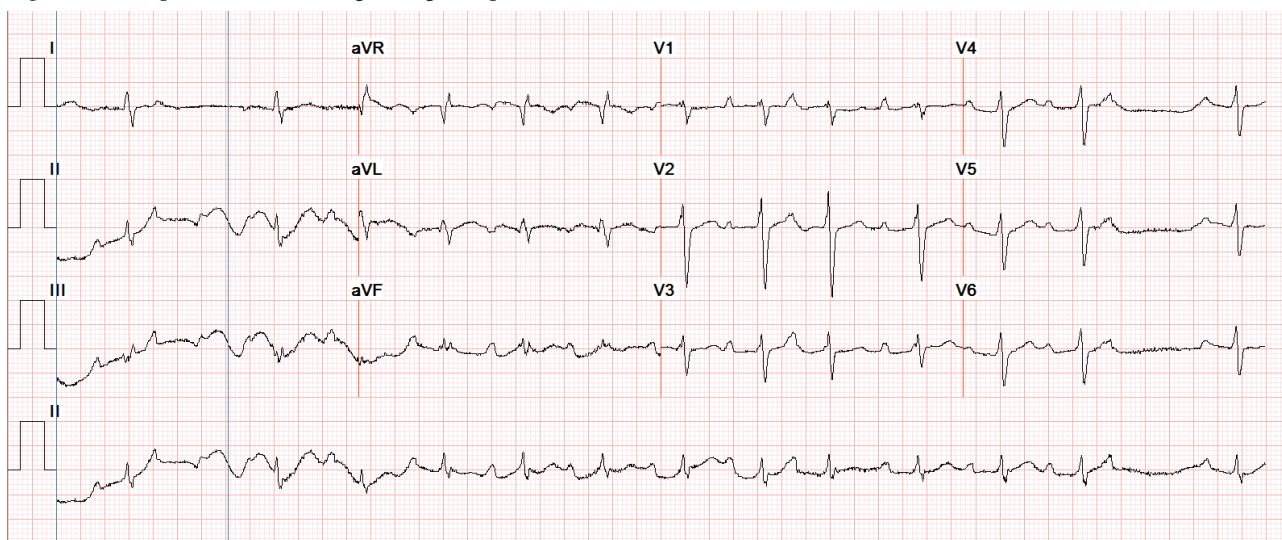


Figure 3-C The patient's ECG tracing from 3 months ago.

4. A 67-year-old man with a history of extensive urologic surgery for bladder cancer develops new-onset atrial fibrillation in the medical ICU. He was admitted 18 h ago with septic shock due to urinary tract infection. Urine and blood cultures demonstrate growth of *Klebsiella* species. He was initially treated for hypotension with Ringer's lactate solution, 30 mL/kg bolus; and piperacillin/tazobactam. His serum lactate concentration on admission was 46 mg/dL (5.1 mmol/L), and it is now 17 mg/dL (1.9 mmol/L). He required a norepinephrine infusion at a rate of 0.12 μ g/kg/min previous to the arrhythmia, but is now requiring 0.3 μ g/kg/min. His mean arterial pressure is 65 mm Hg, and his pulse rate is ranging from 110/min to 147/min. His daughter, an internist from out of state, is at the bedside. She wants to know whether his new-onset atrial fibrillation affects his prognosis. He has no previous cardiac history. Which should you tell her about his mortality risk?

- A. Mortality risk is at least 7% higher than sepsis without atrial fibrillation.
- B. Mortality risk is no different with or without atrial fibrillation.
- C. Mortality risk is unaffected by norepinephrine-provoked atrial fibrillation.
- D. Mortality risk is paradoxically lower by 10% in those developing atrial fibrillation.

5. A 2015 trial compared two massive-transfusion strategies in patients with trauma and hemorrhagic shock: fresh frozen plasma, platelets, and RBCs given in either a 1:1:1 or a 1:1:2 ratio. Compared with the 1:1:2 ratio, patients receiving blood products in the 1:1:1 ratio strategy had which of the following?

- A. Higher incidence of transfusion-related acute lung injury
- B. Higher mortality at 30 days
- C. Lower mortality at 30 days
- D. Less exsanguination and death at 3 h

6. An 81-year-old college professor was admitted to the hospital during the month of July with mental status changes developing over 2 days. Associated with the mental status changes were a reported fever, rigors, myalgias, hand tremors, and lower-extremity weakness manifested by difficulty walking. Examination revealed disorientation, an intention tremor, and weakness of the left lower extremity. The patient's weakness progressed, he continued to have fever, and he had worsening cognition. He required transfer to the ICU and intubation.

The patient had a past history of hypertension, diabetes, paroxysmal atrial flutter, and sick sinus syndrome. He lived in an urban area of a large North American city, and commuted to class daily by riding his bike during summer months.

Findings on a CT scan of the head were normal. Findings on an electroencephalogram were consistent with moderate encephalopathy with no epileptiform activity. Cerebrospinal fluid (CSF) analysis demonstrated pleocytosis (24 cells/ μL) with lymphocyte predominance (81%), increased protein (0.068 g/dL [0.68 g/L]), a normal glucose level (64 mg/dL [3.6 mmol/L]), and a negative gram stain. CSF serology was positive for West Nile virus IgM at a titer of 1:3.83. Testing of the CSF for IgM antibodies related to other regional arboviruses was negative.

Which of the following choices is correct?

- A. The patient meets diagnostic criteria for neuroinvasive West Nile virus infection.
- B. Urban dwellers are unlikely to be infected with West Nile virus.
- C. Neutrophils are the predominant cell type seen in the CSF in most cases of West Nile virus infection.
- D. IgM antibody capture enzyme-linked immunosorbent assay for West Nile virus distinguishes West Nile infection from that of other flaviviruses.

7. After a 3-year period of drought, the Mississippi River overflows its banks in northern Louisiana and causes flooding. Four weeks following this, a 29-year-old cotton farmer who resided in that area began complaining of severe back pain and decreased urination. Despite self-treatment with ibuprofen, his symptoms worsened over the next 3 days, and he began having increasing dyspnea without cough, nausea, vomiting, diarrhea, or fever. Physical examination at the time of presentation was remarkable for a respiratory rate of 32/min, pulse 128/min, temperature of 38.6°C, and BP of 136/62 mm Hg.

A chest roentgenogram demonstrated bilateral alveolar infiltrates. Pertinent laboratory study results were hematocrit of 58.9%; WBC count of 20,800/ μL ($20.80 \times 10^9/\text{L}$), with 81% polymorphonuclear leukocytes and 6% bands, and the presence of immunoblasts; platelet count of 72,000/ μL ($72 \times 10^9/\text{L}$); BUN level of 35 mg/dL (12.5 mmol/L); creatinine level of 1.9 mg/dL

(168 $\mu\text{mol/L}$); prothrombin time of 10.4 s; partial thromboplastin time of 44 s; aspartate aminotransferase level of 124 U/L (2.1 $\mu\text{kat/L}$); and lactate dehydrogenase level of 1,668 U/L (28 $\mu\text{kat/L}$). Arterial blood pH on room air was 7.44, Pco_2 was 22 mm Hg, and Po_2 was 59 mm Hg. Examination of urinary sediment showed 11 RBCs per high-power field with no casts.

The patient's condition continued to deteriorate over the next 2 days, with intermittent temperatures up to 40.2°C and creatine kinase elevations to 1,171 U/L (19.6 $\mu\text{kat/L}$) despite hydration, oxygenation, and broad-spectrum antimicrobial therapy. The worsening of his clinical illness led to initiation of ventilatory support for progressive hypoxemia and renal replacement therapy for worsening azotemia. Based on this clinical and laboratory presentation, which is the most likely presumptive diagnosis in this patient?

- A. Granulomatosis with polyangiitis (Wegener)
- B. Systemic lupus erythematosus
- C. Hantavirus pulmonary syndrome
- D. Leptospirosis

8. A 63-year-old woman is admitted to the ICU reporting a history of having one black stool daily for the last 3 days and one episode of hematemesis. The patient is a known alcoholic and states that she has not had anything to eat for 2 weeks. On admission, her BP is 118/46 mm Hg, heart rate is 100/min, respiratory rate is 22/min, and the patient is afebrile. The oxygen saturation is 100% by a pulse oximeter on 2 L/min of supplemental oxygen by nasal cannula. Examination reveals a thin woman in no acute distress with numerous cutaneous insect bites and scratch marks; there is evidence of the presence of bed bugs (*Cimex lectularius*). An ECG demonstrates tachycardia but no evidence of ischemia, a chest radiograph demonstrates no acute disease, and an echocardiogram demonstrates a normal left ventricular ejection fraction. Selected laboratory test results are shown in Table 8-A.

Assuming a cardiac output of 10 L/min, which of the following is true for this patient?

- A. The oxygen consumption is approximately 1,500 mL/min.
- B. Oxygen consumption can be shown to be independent of oxygen delivery in this patient.
- C. The oxygen delivery is approximately 295 mL/min.
- D. The oxygen content is approximately 16.5 mL/dL.

Table 8-A Selected Laboratory Test Results for the Patient in This Scenario

| | | |
|-------------------|---------------------------------------|------------------|
| White blood count | 21.5 K/uL (21.5 x 10 ⁹ /L) | 3.8-10.6 K/uL |
| Hemoglobin | 2.2 g/dL (22 g/L) | 12.0-15.0 g/dL |
| Platelet count | 198 k/uL (198 x 10 ⁹ /L) | 150-450 K/uL |
| Sodium | 145 mmol/L | 135-145 mmol/L |
| Potassium | 3.9 mmol/L | 3.5-5.0 mmol/L |
| Creatinine | 1.13 mg/dL (99.9 $\mu\text{mol/L}$) | <1.03 mg/dL |
| Lactate | 17.0 mmol/L | 0.4-1.8 S mmol/L |

9. A 73-year-old man is being considered for liberation from ventilatory support in the ICU. He was initially admitted to the ICU with community-acquired pneumonia and sepsis. Comorbidities include a history of systolic cardiac dysfunction with a reported left ventricular ejection fraction between 30% and 35% by echocardiography, chronic atrial fibrillation, COPD, diabetes mellitus, and hypertension.

His vital signs are stable. The patient has no focal neurologic findings and responds to simple commands. His physical examination is otherwise normal except for peripheral edema and the presence of a Foley catheter, an endotracheal tube, and a nasogastric tube. The patient demonstrates a gag reflex and has a strong cough upon stimulation of the airways during suctioning. Serum electrolyte levels are normal except for an elevated serum sodium level (150 mmol/L [150 mEq/L]).

The patient is receiving ventilatory support with a pressure-regulated volume-control mode, an FIO_2 of 0.4, a set respiratory rate of 14/min (total respiratory rate: 24/min), and a PEEP of 5 cm H_2O . An arterial blood gas analysis demonstrates a pH of 7.42, a PCO_2 of 48 mm Hg, and PO_2 of 104 mm Hg. A spontaneous breathing trial is conducted for 60 min with a PEEP of 5 cm H_2O with an inspiratory augmentation of 7 cm H_2O . At the end of this trial, the patient's rapid shallow breathing index (RSBI) is 50 breaths/L.

Which is true about high-risk patients receiving ventilatory support who have passed a spontaneous breathing trial?

- A. The risk of reintubation within 48 h is <5%.
- B. Immediate mask ventilation following extubation reduces reintubation rates and shortens ICU stay.
- C. The RSBI is a threshold function rather than a continuous function in the prediction of successful liberation.
- D. Hypernatremia is a well-established risk factor for failed liberation.

10. The use of the intraosseous route for vascular access during resuscitation does which of the following?

- A. Permits administration of crystalloids but not blood products
- B. Is recommended if difficulty acquiring venous access is encountered
- C. Requires that catecholamine doses be significantly increased above the doses recommended for IV administration
- D. Requires more time to achieve than placement of a central venous catheter

11. A 52-year-old homeless man is brought to the ED by the emergency medical service after being found unresponsive by his friend. His past medical history is notable for noninsulin-dependent diabetes and mild hypertension. He has been homeless for 2 years. He has a known history of alcohol abuse but no reported illicit drug use. He smokes one pack of cigarettes per day. His friends report that he has been out of money for the past week.

On physical examination, the patient's vital signs are as follows: temperature, 36°C; BP, 100/70 mm Hg; heart rate, 80/min; and respiratory rate, 12/min. There is a fruity odor to his breath. The patient is disheveled, his lungs are clear, there are no murmurs, findings of abdominal examination are normal, and extremities reveal trace edema and some excoriations. Neurologic examination reveals a minimally responsive, disoriented patient; otherwise neurologic findings are normal. His pupils are 3 mm bilaterally with mild nystagmus, chest radiograph is clear, and head CT scan is unremarkable except for some mild ventricular atrophy.

Laboratory studies reveal the following levels: sodium, 130 mEq/L (130 mmol/L); potassium, 4 mEq/L (4 mmol/L); chloride, 100 mEq/L (100 mmol/L); bicarbonate, 23 mEq/L (23 mmol/L); urea nitrogen, 24 mg/dL (8.6 mmol/L); creatinine, 1.4 mg/dL (123.8 $\mu\text{mol/L}$); glucose, 240 mg/dL (13.3 mmol/L); and lactate, 15.32 mg/dL (1.7 mmol/L). There are large amount of ketones in both the serum and urine. Analysis of an arterial blood gas sample collected with the patient receiving 2 L/min oxygen via nasal cannula reveals the following: pH, 7.40; PCO_2 , 35 mm Hg; and PO_2 , 80 mm Hg. His ethanol level is negative, urinalysis is otherwise unremarkable, and measured serum osmolality is 310 mOsm/kg (310 mmol/kg).

Which is a likely explanation for this presentation?

- A. Methanol intoxication
- B. Ethylene glycol intoxication
- C. Isopropyl alcohol intoxication
- D. Starvation ketosis

12. Following a sentinel event, you, as ICU Medical Director, are asked to prepare a document that summarizes the incidence, risk factors, and consequences of unplanned endotracheal tube extubation in the ICU. Based upon published literature, which of the following statements is most correct?

- A. Approximately 20% of intubated patients in the ICU undergo unplanned extubation.
- B. Increased level of consciousness is associated with a higher likelihood of unplanned extubation.
- C. Routine use of physical wrist restraints is effective to prevent unplanned extubation.
- D. Approximately 10% of patients in the ICU who have unplanned extubation require reintubation.

13. Which of the following statements is true regarding sedatives commonly used in critically ill patients?

- A. Propofol acts as a selective α_2 -adrenergic agonist.
- B. Dexmedetomidine is excreted unchanged in the urine, so dose adjustments are required in patients with renal impairment, but not liver disease.
- C. Lorazepam has been shown to be a risk factor for the development of delirium in patients receiving ventilatory support.
- D. Dexmedetomidine and midazolam have similar rates of short-term adverse effects in critically ill patients.

14. A 36-year-old black woman (gravida 3, para 2) in the 37th week of pregnancy comes to the labor and delivery emergency clinic with the gradual onset of steadily worsening shortness of breath over the past week, which has worsened markedly over the past 24 hours. She reports the inability to lie flat and worsening lower extremity edema. She reports subjective low-grade fevers but did not take her temperature at home, and a cough productive of mostly whitish sputum but with some pink tinge to the sputum on the day of presentation. She denies chest pain.

On examination, the patient is in moderate respiratory distress. Vital signs are as follows: heart rate of 120/min, respiratory rate of 18/min, BP of 108/70 mm Hg, and temperature of 38°C. SpO_2 is 91% on 3 L/min oxygen via nasal cannula. A neck examination shows increased jugular venous pressures, lung auscultation reveals crackles, and a cardiac examination reveals tachycardia. Abdominal examination reveals a gravid uterus and there is 2+ symmetrical pedal edema.

Laboratory study results are notable for a WBC count of 12,000/ μL ($12 \times 10^9/\text{L}$) with a normal differential, a hemoglobin level of 10 g/dL (100 g/L), and platelet count of 150,000/ μL ($150 \times 10^9/\text{L}$). Chemistry and liver function test results are normal. Urinalysis reveals 50 WBC per high-power field as well as bacteria, and the urine is nitrite positive.

The patient is admitted to the medical ICU for further management. Her chest radiograph is shown (Figure 14-A).

Which is this patient's most likely diagnosis?